

Experimental study on the healing process following laser welding of the cornea

Francesca Rossi

Roberto Pini

Consiglio Nazionale delle Ricerche
Istituto di Fisica Applicata
Firenze, Italy

Luca Menabuoni

Unità Operativa Oculistica
Azienda USL 4
Prato, Italy

Rita Mencucci

Ugo Menchini

Università di Firenze
Dipartimento di Scienze Oto-Neuro-Oftalmologiche
Italy

Stefano Ambrosini

Gabriella Vannelli

Università di Firenze
Dipartimento di Anatomia
Italy

Abstract. An experimental study evaluating the application of laser welding of the cornea and the subsequent healing process is presented. The welding of corneal wounds is achieved after staining the cut walls with a solution of the chromophore indocyanine green, and irradiating them with a diode laser (810 nm) operating at low power (60 to 90 mW). The result is a localized heating of the cut, inducing controlled welding of the stromal collagen. In order to optimize this technique and to study the healing process, experimental tests, simulating cataract surgery and penetrating keratoplasty, were performed on rabbits: conventional and laser-induced suturing of corneal wounds were thus compared. A follow-up study 7 to 90 days after surgery was carried out by means of objective and histological examinations, in order to optimize the welding technique and to investigate the subsequent healing process. The analyses of the laser-welded corneas evidenced a faster and more effective restoration of the architecture of the stroma. No thermal damage of the welded archa was detected, nor were there foreign body reactions or other inflammatory processes. © 2005 Society of Photo-Optical Instrumentation Engineers. [DOI: 10.1117/1.1900703]

Keywords: laser welding; diode laser; cornea; penetrating keratoplasty.

Paper 04165 received Aug. 24, 2004; revised manuscript received Nov. 3, 2004; published online Apr. 11, 2005; accepted for publication Nov. 4, 2004; published online. This paper is a revision of a paper presented at the SPIE conference on Ophthalmic Technologies XIV, July 2004, San Jose, California. The paper presented there appears (unrefereed) in SPIE Proceedings Vol. 5314.

1 Introduction

In the last two decades, laser welding of biological tissue has been tested, mainly at an experimental level, in various surgical applications, such as the repair of blood vessels, nerves, tendons, bronchial fistulae, skin, etc.^{1,2} It was proposed as an alternative technique or a supporting tool to conventional suturing procedures in order to reduce the typical inflammatory processes, such as foreign body reaction, following the application of stitches, as well as to facilitate suturing operations in particular surgery conditions such as in microsurgical and endoscopic applications. Many reported studies on laser-induced welding techniques have pointed out the possibility to perform effective tissue closure with minimal side effects, and to induce an improved healing process, where the restored tissue is much more similar to the native one.

To achieve these goals, the choice of the laser emission parameters (wavelength and energy dose), as well as of the principal absorber of the tissue targeted by laser radiation are critical factors. Since the major component of biological tissue is water, earlier reported experiments have been based on the use of water as an endogenous chromophore to absorb laser light. Various laser types with wavelengths exhibiting high optical absorption in water have been used for this task, such as CO₂ (10.6 μm), holmium:YAG (2100 nm), erbi-

um:YAG (2900 nm), and diode lasers (1900 nm). The main problem with such laser wavelengths is that, without an adequate control of the dosimetry and of the induced temperature rise, the outermost tissue layers can be affected by serious heat damage, whereas the deeper layers are hardly heated at all, resulting in a weak bonding since the full thickness of the tissue is not involved in the welding process.

Improved results in tissue welding were observed by using exogenous chromophores to absorb laser light, sometimes in association with protein solders. Addition of highly absorbing dyes to the solders allowed fusion of wounds at lower irradiation fluences, thus avoiding excessive thermal damage to the surrounding tissues. In fact, the usage of a chromophore was found to induce a controllable temperature rise only in the area where it had been previously applied, resulting in a selective thermal effect.

In ophthalmology, experimental studies of laser-induced suturing of corneal tissue on animal models have been reported since 1992 by various authors,³⁻¹¹ based on the use of near- and far-infrared lasers, directly absorbed by the water content of the cornea. In some cases, experimental results were not considered satisfactory^{6,7} since the direct absorption of laser light in a short penetration depth of the outer stroma caused a high temperature rise at the irradiated surface, followed by collagen shrinkage and denaturation. With CO₂ la-

Address all correspondence to Roberto Pini, IFAC-CNR, Via Madonna del Piano s.n., Sesto Fiorentino, 50019 Italy

sers, better results were achieved when the temperature was controlled during irradiation.⁸⁻¹¹

The technique we employed in the experiments reported here, as well as in previous studies,¹²⁻¹⁴ is based on the use of near-infrared diode laser radiation at 810 nm, in association with the topical application of a solution of indocyanine green (ICG) to the corneal wound to be repaired. This dye is characterized by high optical absorption around 800 nm¹⁵ while the stroma is almost transparent at this wavelength.¹⁶ ICG is a frequently used ophthalmic dye, with a history of safety in humans. It is being used increasingly as an intraocular tissue stain in cataract and vitreoretinal surgery, as well as in staining the retinal internal limiting membrane.^{17,18} Beside this, ICG is commonly used in laser welding or laser soldering as a chromophore^{1,2} in order to induce differential absorption between the dyed region and the surrounding tissue. Photothermal activation of the stromal collagen is thus induced by laser radiation only in the presence of ICG, resulting in a selective welding effect, which produces an immediate sealing of wound edges and good mechanical strength. In addition, with the use of ICG, very low laser power is required (below 100 mW) and this generally allows much safer operations than those in which other laser types are used without associated dyes.

The interest in characterizing laser-induced welding of the cornea is related to the possibility of setting up an improved suturing technique to be used in ophthalmic surgery applications, such as in penetrating keratoplasty (transplant of the cornea), in cataract surgery (in particular for extra-capsular cataract extraction), and in the treatment of accidental corneal perforations. The potential advantages which are expected by this technique are: simplification of the surgical technique and reduction of the intervention time, suppression of suture materials and thus of foreign body reaction, reduction and control of post-operative astigmatism. Moreover, previous experiments on the cornea^{13,14} and on other kinds of tissue¹⁹⁻²¹ provided some preliminary indications that the healing could be faster in comparison with conventional surgery.

In order to verify these interesting features, we arranged *in vivo* tests on animal models, performing objective observations and histological analysis at follow-up times of up to three months. This study allowed comparison of the healing process after laser-induced welding of the cornea with that of conventional stay suturing.

2 Materials and Methods

In vivo experiments were performed on 34 New Zealand albino rabbits weighing 2.5 to 3.5 kg. To undergo the procedure, they were anaesthetized with diazepam (5 mg/kg) and ketamine hydrochloride (75 mg/kg) intramuscularly. Protocols of animal tests were designed according to the recommendations and the regulations of the Italian Health Ministry.

The chromophore used in laser welding tests was IC-GREEN™ (Akorn, Buffalo Grove, IL). Various pharmaceutical formulations of ICG were set up and tested during *in vivo* experimental procedures: (1) ICG saturated solution in sterile water; (2) semi-solid formulations employing biocompatible polymers (sodium hyaluronate, polyvinyl alcohol, and TSP™ by Farmigea, Pisa, Italy), with ICG concentrations ranging from 0.5% to 10% w/w. Most of the surgical trials were car-



Fig. 1 The diode laser and the fiber hand piece.

ried out by using high-concentration ICG solution in sterile water (around 12% w/w) which performed quite well in all cases. This very dense preparation was viscous enough to be easily placed inside the corneal cut, using an anterior chamber cannula. Particular care was taken to avoid perfusion of the dye in the anterior chamber, where a bubble of air had been previously injected. A few minutes after the application, the solution was washed out with abundant water. The stained walls of the cut appeared greenish, indicating that the concentration of ICG absorbed by the stroma was much lower than that of the applied solution, but sufficient to produce an effective welding of the tissue. In this respect, a more precise evaluation of the ICG absorption curve when dissolved in corneal collagen would be important to quantify the concentration of residual ICG in order to prove that it was not toxic. Such a study is presently in progress and will be the object of a future report.

The laser used was a AlGaAs diode laser (produced by EL.EN. spa, Calenzano, Italy), emitting at 810 nm, with a maximum power output of 10 W. The device was enclosed in a compact cabinet, 24×18×36 cm (see Fig. 1) and equipped with a fiber optic delivery system employing fibers with 200- and 300- μm -core diameters. Each fiber terminated in a hand piece, which enabled easy handling under a surgical microscope.

2.1 Surgical Procedures

In vivo tests were divided into two groups:

Group 1: Four rabbits out of the 34 were selected to perform surgical trials simulating penetrating keratoplasty (PK), in order to evaluate the practical aspects of this technique. Two animals (indicated hereinafter as Laser Group 1) were subjected to laser-induced suture of the corneal button. The surgical procedure was the following: after trephination with an 8-mm-diameter trephine, the corneal button was excised, placed again into the same eye, and sutured by 8 to 10 interrupted stitches (10-0 Ethilon nylon wire) located at equally spaced intervals along the circular cut. The ICG solution was applied by means of an anterior chamber cannula inserted within the intervals between each couple of stitches, in an attempt to stain the walls of the cut in-depth. The corneal surface was then washed with water. The operation was repeated until ICG was absorbed by the cut walls, as evidenced by a greenish appearance. Lastly, the whole length of the cut was subjected to laser irradiation. The other two rabbits (Control Group 1) were subjected to conventional PK by means of



Fig. 2 Laser welding of a corneal cut supported by a single stitch in the middle. The dark color of the cut walls is due to the ICG solution applied prior to laser irradiation.

the application of a continuous suture along the corneal button, in addition to the same number of interrupted stitches.

Group 2: We performed laser welding tests on corneal cuts of shorter length on 30 rabbits, in order to evaluate the healing process during follow-up. The cuts were performed in the periphery around the external perimeter of the cornea button, as shown in Fig. 2.

In the right eyes of the animals a full thickness cut 5 mm in length was produced by a precalibrated knife (similar to that used in cataract surgery); a single stitch was then applied to the middle of the cut. The cut was stained with the ICG solution and irradiated by laser light. These eyes composed Laser Group 2. The left eye of each animal (Control Group 2) was subjected to the same procedure, but without laser treatment. This enabled us to compare, in the same animal at a certain time after surgery, the repair process of the cornea provided by both laser-induced and conventional suturing.

2.2 Follow-up Procedure

Group 1: Two rabbits were subjected to follow-up on seven post-operative days and two rabbits to follow-up on 15 days. At these times, each animal was re-anaesthetized in order to permit examination, by microscope observation, of the morphology of the cornea.

Group 2: Animals which underwent tests on laser welding of corneal cuts were divided into five sub-groups, each one subjected to a follow-up on 7, 15, 30, 60, 90 days, respectively. At these times animals were sacrificed. The ocular bulb was excised, and a 10×5 mm portion of the cornea including the cut (clearly detectable from the stitch applied to the middle of the cut) was removed, immersed in formalin, and prepared for successive examination. The corneal samples were included in paraffin and sectioned by a microtome. Histological slices were colored with hematoxylin and eosin.

In order to study collagen organization after laser treatment, a few samples were studied using immunohistochemistry techniques. The slides, deparaffinized and rehydrated, were exposed to 3% hydrogen peroxide solution, to quench endogenous peroxidase activity. Slides were rinsed in tap water, then immersed in EDTA (pH 8) and microwaved, to en-

hance antigen exposure. The primary antibody at the appropriate dilution (1:500 monoclonal anti-collagen type I clone col-1) in PBS was added to the slides and incubated overnight at 4 °C. Sections were rinsed in PBS, incubated with biotinylated secondary antibody, and then reincubated with streptavidin biotin peroxidase complex. The reaction product was developed with the deaminobenzidine tetrahydrochloride as chromogen (Chemicon IHC Select Kit, Chemicon International, Inc. Temecula, CA, USA). Slides were washed in running tap water followed by dehydration and coverslip mounting. Controls were performed by processing slides lacking the primary antibody or stained with the corresponding nonimmune serum and counterstained with hematoxylin.

3 Results

3.1 Observations at the Time of Surgery

For Groups 1 and 2, a diode laser power ranging from 60 to 90 mW was found to be suitable to induce the welding of corneal cuts without visible side effects. These power values corresponded to power densities at the surface of the cornea ranging from 6 and 23 W/cm², calculated by considering that the tip of the 300- μ m-core fiber was typically kept at a distance of 1 to 2 mm from the cornea. The welding effect on corneal tissue was observed to be selectively localized within the cut, with no heat damage to the adjacent tissue. The cut walls could be homogeneously irradiated and welded by keeping the fiber at a small angle with respect to the corneal surface ("side irradiation" technique). The achievement of an effective welding of corneal wounds was shown by a slight whitening of the cut walls, which developed during laser irradiation, as was observable by the microscope. At a higher laser power, i.e., greater than 120 mW, the whitening of the corneal stroma became stronger, indicating the formation of some thermal coagulation within the cut. Laser irradiation times depended on the length of the corneal cut: typically, 200 s for Group 1 (25 mm cut length), and 50 s for Group 2 (5 mm cut length).

Control of the temperature variations on the surface of the cornea was performed using an infrared camera (AGEMA 880 LWB). All the recorded images showed that the temperature rise was confined to the zone directly exposed to laser radiation, where ICG had been previously applied. The temperature rise values varied depending on laser power: for the typical power range of 60 to 90 mW, the temperature rise was about 10 to 15 °C. When using higher power values, greater than 120 mW, the measured temperature rise was greater than 30 °C: the welded tissue showed some traces of local damage of the stroma, as evidenced by different degrees of coagulation, depending on the irradiation conditions.

3.2 Follow-up Results

3.2.1 Morphological observations on Group 1 (PK surgery tests)

Laser Group 1: The ICG solution was completely reabsorbed after one to three postoperative days. On the seventh day after surgery, the epithelium was restored. At the cut edges, the stroma showed a modest edema. On day 15, the cornea ap-

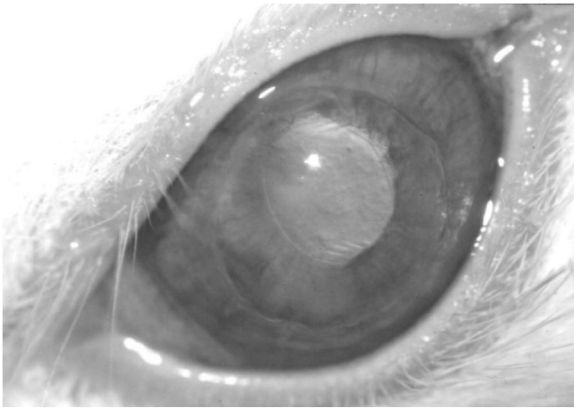


Fig. 3 Aspect of a rabbit cornea 15 days after laser-assisted PK. The interrupted stitches supporting the button have been removed (Laser Group 1).

peared transparent and well-restored (see Fig. 3). After the interrupted stitches were removed, the corneal button showed good adhesion to the outer cornea.

Control Group 1: The repair process appeared to be delayed with respect to that of the previous group. In one of the two cases on day 15 (Fig. 4), a significant edema around the cut edge was observed. In the other case, the aspect of the cornea was better; however, after removal of the continuous suture, the adhesion of the cut edges was found to be very poor.

3.2.2 Histological results on Group 2 (laser welding of short cuts)

Significant results were obtained from histological examinations. The healing process following laser welding appeared to start earlier than in the case of the control group: in the cut area of a laser-treated cornea on the seventh post-operative day the migration of both abundant connective stromal tissue was clearly visible and the epithelium appeared restored, even though significantly thicker than the physiological one. In Control Group 2, on the seventh day we did not observe a similar formation of connective tissue within the cut walls. On the 15th post-operative day in Laser Group 2, no specimen

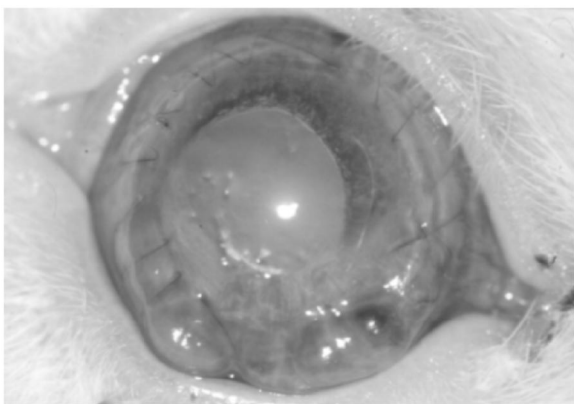


Fig. 4 Aspect of a rabbit cornea 15 days after traditionally sutured PK. The corneal button has an edematous appearance and poor adhesion in the cut area (Control Group 1).

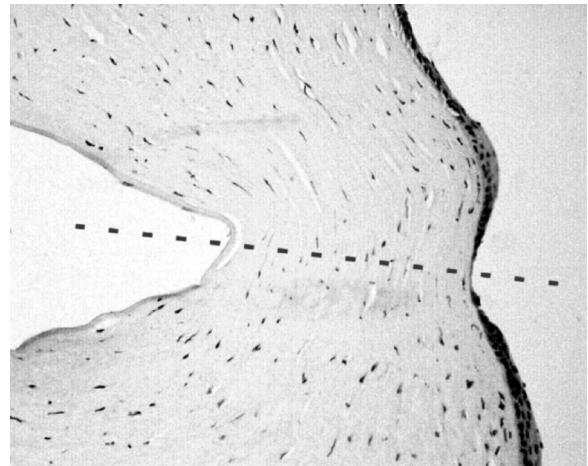


Fig. 5 Histological section of a cornea of Laser Group 2, 15th post-operative day (magnification 80 \times). In the area of the cut (dashed line), the epithelium shows a variation in thickness and the stroma is densely restored by connective collagen tissue organized in parallel lamellae, even if some lacunae are observable.

from laser-sutured corneas showed phlogistic reaction: the stroma was revealed to be densely restored by connective collagen tissue, organized in parallel lamellae (Fig. 5), while the epithelium showed some variations in thickness. Instead, intense inflammatory processes were found to be still active at the same post-operative day in slices obtained from Control Group 2, as shown in Fig. 6.

At longer follow-up times, evidence of a faster healing process was observed in samples from Laser Group 2 in comparison with Control Group 2: the architecture of the cornea appeared to have regained an almost physiological appearance after 30 days from surgical procedure (Fig. 7), while in the control group the cut area was still clearly detectable and partially filled by the epithelium (Fig. 8). On the 60th day, the cut region was well-restored, as shown in Fig. 9: the epithelium had a regular width, the same as the healthy cornea,

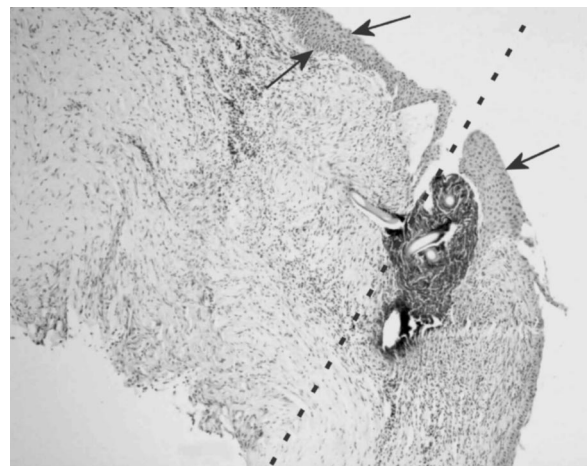


Fig. 6 Histological section of a cornea, Control Group 2, 15th post-operative day (magnification 80 \times). In the area of the cut, the epithelium (arrows) is very thick and the stroma shows a chaotic structure with abundant keratocytes and blood cells, indicating strong inflammatory and foreign body reactions at this site.

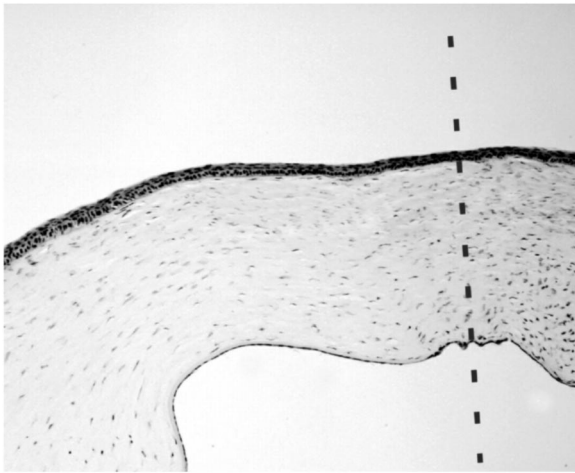


Fig. 7 Histological section of a cornea, Laser Group 2, 30th post-operative day (magnification 50×). The architecture of the cornea seems to have regained an almost physiological appearance, as evidenced by the advanced repair process involving epithelium, stroma, and endothelium.

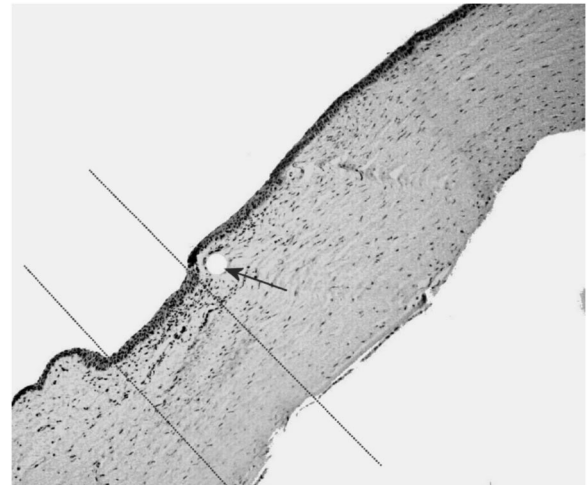


Fig. 9 Histological section of a cornea, Laser Group 2, 60th post-operative day (magnification 50×). The epithelium width in the wound area (within the dotted lines) is equal to the one of the healthy area. No lacunae nor vessels are detectable, and the stromal fibers are very regular. The circular hole (arrow) was produced by the suturing thread.

and stromal fibers were very regular. On the 90th day (Fig. 11) the results were similar to the previous one, and the cornea looked well-restored. On the other hand, the repair process in cornea specimens from Control Group 2 was still in progress at the same post-operative times: on day 60 (Fig. 10), the restored epithelium was thinner than in the surrounding area, while on day 90 (Fig. 12) it had an irregular profile and was thickening. A number of vessels were detectable in the area of the wound and crowded keratocytes were observable in the upper zone. Figure 12 clearly shows the difference between the repaired collagen in the central area of the cut and the collagen outside the wound. This difference was not found in any of the laser-treated rabbit corneas.

3.2.3 Immunohistochemical results (Group 2)

Immunohistochemistry was used to study a number of cornea samples, in order to evaluate collagen organization after suturing. Collagen fibers were clearly detectable in all the recorded images both in the Laser Group 2 and in the Control Group 2 samples, at 60 to 90 post-operative days. In Fig. 13 an image of a slice from a laser-welded rabbit cornea on the 90th post-operative day is shown: the collagen fibers had a linear and homogeneous pattern. Figure 14 displays an example of a traditionally sutured rabbit cornea, at the same day: the collagen fibers had a sinusoidal pattern, which probably reflects the release of stroma tension forces. Irregular collagen formation was clearly visible, appearing as black dots.

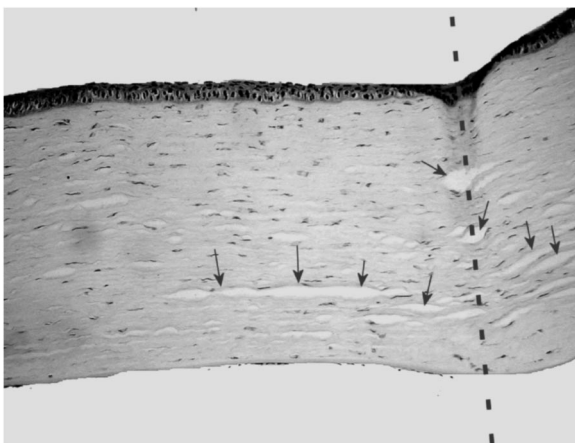


Fig. 8 Histological section of a cornea, Control Group 2, 30th post-operative day (magnification 80×). The cut (dashed line) is still clearly detectable and partially filled by the epithelium. Large lacunae (arrows) are evident at the site of the lesion and in the adjacent regions of the stroma.

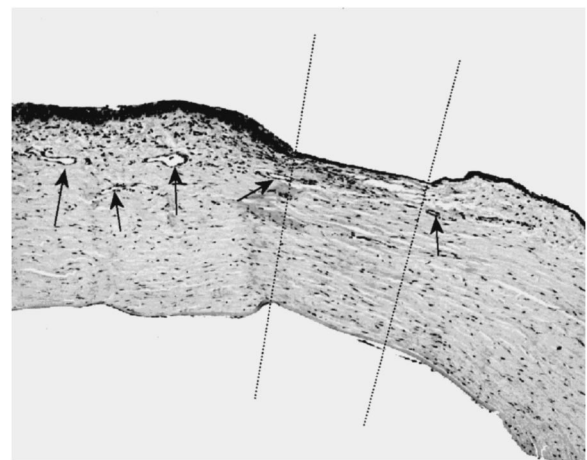


Fig. 10 Histological section of a cornea, Control Group 2, 60th post-operative day (magnification 50×). The repair process is still in progress: the epithelium is very thin in the wound area (between dotted lines); there is stromal vascularization (arrows), crowded keratocytes, and stromal lacunae.

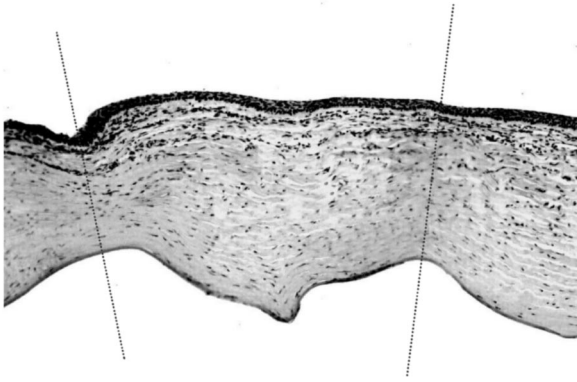


Fig. 11 Histological section of a cornea, Laser Group 2, 90th post-operative day (magnification 50×). The cornea is well restored, with regular stromal fibers. Worth noting is the compartmentalization of keratocytes, mainly located in the outer layers of the stroma.

4 Conclusions

Regarding the observations at the time of surgery, the very large number of tests on laser-assisted repair of cuts of short length (5 mm) allowed us to find the optimal type of ICG solution and laser power to perform high-quality laser welding of corneal tissue: ICG solution in water and diode laser power as low as 60 to 90 mW at 810 nm gave the best results in terms of mechanical strength, scattering properties, and morphology of laser-repaired corneal wounds. Moreover, tests simulating penetrating keratoplasty, even though performed in just four eyes, offered preliminary indications on the clinical feasibility of this procedure: laser welding of the perimeter of the corneal button could be successfully performed in lieu of the continuous suture, providing a watertight closure of the wound, requiring operation times of a few minutes, which included the time for the application of ICG to the wound and about 200 s for laser irradiation of the whole cut length.

Then the healing process following laser-induced suturing was studied. Results obtained by morphological, histological,




Fig. 13 Immunohistochemical analysis of a cornea, Laser Group 2, 90th post-operative day (magnification 80×). The collagen fibers are very regular in all the wound area.

and immunohistochemical analysis were quite significant and confirmed preliminary analysis and previous studies on different types of tissue. We found that the repair process of laser-welded corneal wounds started earlier than that of traditionally sutured wounds: objective observations at two weeks after surgery showed a good morphology of laser-treated corneas, with almost restored cuts, generally characterized by better adhesion and lesser edematous appearance as compared to the sutured ones. These features were confirmed by histological examinations, which showed at this time a well-developed repair process in the Laser Group, involving the epithelium, which almost regained the physiological continuity and thickness, and a partially reorganized architecture of the stroma. In comparison, in the Control Group on day 15 an intense inflammatory reaction was found, evidenced by a chaotic organization of the stroma. Histological analysis on longer follow-up times indicated that the healing of laser-welded wounds was completed in about 30 to 60 days, while in sutured wounds the healing process was still in progress, as

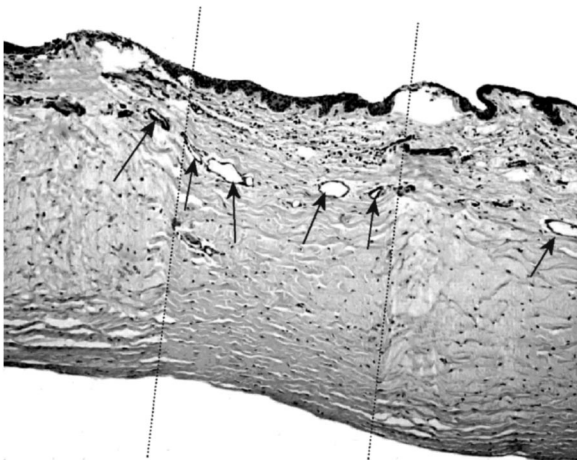


Fig. 12 Histological section of a cornea, Control Group 2, 90th post-operative day (magnification 80×). The repair process is still in progress: the epithelium is growing (with respect to the 60th post-operative day) and has an irregular profile. Vessels are present around the wound area (arrows).

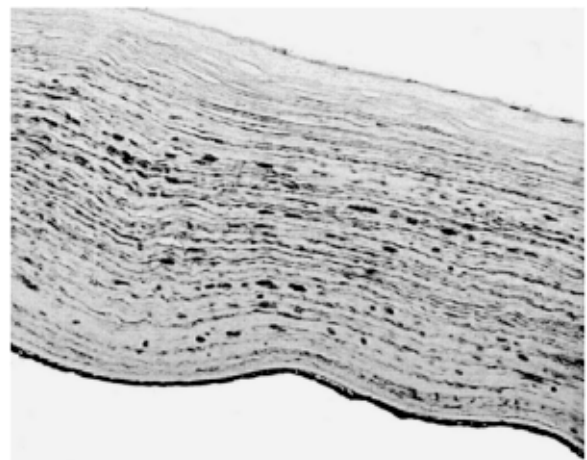

Fig. 14 Immunohistochemical analysis of a cornea, Control Group 2, 90th post-operative day (magnification 80×). Black dots indicate irregular collagen formations.

shown by the irregular epithelium and by the presence of blood vessels, never observed at any time in the Laser Group.

Objective observations during the follow-up pointed out another important result of the laser welding procedure: the restored wound area appeared to have regained the transparency and the shape of the healthy cornea. At the microscopic level, this feature was confirmed by histological and immunohistochemical analysis performed on day 90 (see Figs. 11–14), which showed, in the slices from the Laser Group, collagen fibers with a very linear shape, organized in layers of regular thickness and orientation, while in the Control Group the repaired stroma was composed of collagen structures with irregular distribution, consistent with the typical behavior reported in the literature about the healing of the cornea after suturing with conventional stitches.²²

Another important point emerging from our tests was that microscopy observations and histological analyses never revealed the occurrence of thermal injuries due to the absorption of laser light at the typical power levels which were required to induce effective tissue fusion; in addition, direct temperature measurements on the surface of the cornea during laser irradiation, as performed by an IR camera, indicated that in operative conditions the temperature rise was found to be less than 15 °C. This value, which needs to be confirmed by a suitably developed thermal model (presently in progress) to evaluate heat deposition and propagation in the whole thickness of the cornea, provided an initial positive answer about the safety of this technique.

In conclusion, besides practical indications on the feasibility of diode laser-assisted closure of corneal wounds, which may be useful to set up a clinically usable surgical procedure, this experimental study on animal models pointed out what, in our opinion, can be the real potential of such a technique to make it a valid substitute of conventional suturing: as confirmed by histological analysis owing a quite long follow-up period, the healing process of laser-welded corneal wounds takes place in a shorter time and with less inflammatory reaction compared to that of conventionally sutured wounds. This result is particularly important in corneal tissue, which typically requires a much longer time to be repaired in comparison to other types of tissue, and where the restoration of the native architecture of the stroma is crucial to regain correct vision.

Acknowledgments

The authors wish to acknowledge Giovanni Agati and Monica Monici for microscopy analyses, Silvia Tampucci for preparation of the ICG formulations, and Bernardo Innocenti for measurements with the IR camera. This work was done within the frame of the “Optomed” Project, supported by the Regional Program of Innovative Actions (PRAI) of Tuscany and by DG REGIO of the European Union.

References

1. K. M. McNally-Heintzelman, “Laser tissue welding,” Chap. 39 in *Biomedical Photonics Handbook*, pp. 39-1/39-45, T. Vo-Dinh, Ed., CRC Press, Boca Raton (2003).
2. L. S. Bass and M. R. Treat, “Laser tissue welding: a comprehensive review of current and future clinical applications,” *Lasers Surg. Med.* **17**, 315–349 (1995).
3. N. L. Burnstein, J. M. Williams, M. J. Nowicki, D. E. Johnson, and W. Q. Jeffers, “Corneal welding using hydrogen fluoride laser,” *Arch. Ophthalmol. (Chicago)* **110**, 12–13 (1992).
4. G. T. Timberlake, A. Patmore, A. Shallal, D. McHugh, and J. Marshall, “Thermal and infrared-diode laser effects on indocyanine-green-treated corneal collagen,” *Proc. SPIE* **1882**, 244–253 (1993).
5. J. M. Williams, N. L. Burnstein, M. J. Nowicki, C. J. Zietkiewicz, and W. Q. Jeffers, “Infrared laser welding of rabbit cornea *in vivo*,” *Proc. SPIE* **2393**, 131–136 (1995).
6. T. J. Desmettre, S. R. Mordon, and V. Mitchell, “Tissue welding for corneal wound suture with CW 1.9 micro diode laser: an *in vivo* preliminary study,” *Proc. SPIE* **2623**, 372–379 (1996).
7. G. Trabucchi, P. G. Gobbi, R. Brancato, F. Carones, A. Resti, A. Jansen, and R. Pini, “Laser welding of corneal tissue: preliminary experiences using 810 nm and 1950 nm diode laser,” *Proc. SPIE* **2623**, 380–387 (1996).
8. A. Barak, T. Ma-Naim, M. Belkin, and A. Katzir, “Temperature-controlled CO₂ laser tissue welding of ocular tissues,” *Proc. SPIE* **2971**, 103–105 (1997).
9. A. Barak, O. Eyal, M. Rosner, E. Belotserkousky, A. Solomon, M. Belkin, and A. Katzir, “Temperature-controlled CO₂ laser tissue welding of ocular tissues,” *Surv. Ophthalmol.* **42**, S77–81 (1997).
10. E. Strassman, N. Loya, D. D. Gatton, A. Ravid, N. Kariv, D. Weinberger, and A. Katzir, “Laser soldering of the cornea in a rabbit model using a controlled-temperature CO₂ laser system,” *Proc. SPIE* **4244**, 253–265 (2001).
11. E. Strassman, N. Loya, D. D. Gatton, A. Ravid, N. Kariv, D. Weinberger, and A. Katzir, “Temperature controlled CO₂ laser soldering of pig cornea,” *Proc. SPIE* **4609**, 222–228 (2002).
12. L. Menabuoni, B. Dragoni, and R. Pini, “Preliminary experiences on diode laser welding in corneal transplantation,” *Proc. SPIE* **2922**, 449–452 (1996).
13. L. Menabuoni, F. Mincione, B. Dragoni, G. P. Mincione, and R. Pini, “Laser welding to assist penetrating keratoplasty: *in vivo* studies,” *Proc. SPIE* **3195**, 25–28 (1998).
14. R. Pini, L. Menabuoni, and L. Starnotti, “First application of laser welding in clinical transplantation of the cornea,” *Proc. SPIE* **4244**, 266–271 (2001).
15. M. L. J. Landsman, G. Kwant, G. A. Mook, and W. G. Zijlstra, “Light-absorbing properties, stability, and spectral stabilization of indocyanine green,” *J. Appl. Physiol.* **40**, 575–583 (1976).
16. A. Roggan, U. Binding, W. Wäsche, and F. Zgoda, “Properties of biological tissues,” Chap I-3.1 in *Applied Laser Medicine*, H. P. Berlien and G. J. Mueller, Eds., pp. 73–99, Springer, Berlin, Heidelberg (2003).
17. C. Haritoglou, A. Gandorfer, M. Schaumberger, R. Tadayoni, A. Gandorfer, and A. Kampik, “Light-absorbing properties and osmolarity of indocyanine-green depending on concentration and solvent medium,” *Invest. Ophthalmol. Visual Sci.* **44**(6), 2722–2729 (2003).
18. G. P. Holley, A. Alam, A. Kiri, and H. F. Edelhauser, “Effect of indocyanine green intraocular stain on human and rabbit corneal endothelial structure and viability. An *in vitro* study,” *J. Cataract Refractive Surg.* **28**(6), 1027–1033 (2002).
19. R. Gelli, R. Pini, F. Toncelli, C. Chiarugi, and U. M. Reali, “Vessel wall recovery after diode laser-assisted microvascular anastomosis: clinical and histological analysis on long period follow-up,” *J. Reconstr Microsurg* **13**, 199–205 (1997).
20. A. Capon, E. Souil, B. Gauthier, C. Sumian, M. Bachelet, B. Buys, B. S. Polla, and S. Mordon, “Laser assisted skin closure (LASC) by using a 815-nm diode-laser system accelerates and improves wound healing,” *Lasers Surg. Med.* **28**(2), 168–175 (2001).
21. A. Capon and S. Mordon, “Can thermal laser promote skin wound healing?,” *Am. J. Clin. Dermatol.* **4**(1), 1–12 (2003).
22. T. Nishuda, “Cornea,” Chap. 1 in *Cornea. Fundamentals of Cornea and External Disease, Vol. 1*, J. H. Krachmer, M. J. Mannis, and E. J. Holland, Eds., pp. 3–27, Mosby, St Louis, MO (1997).